

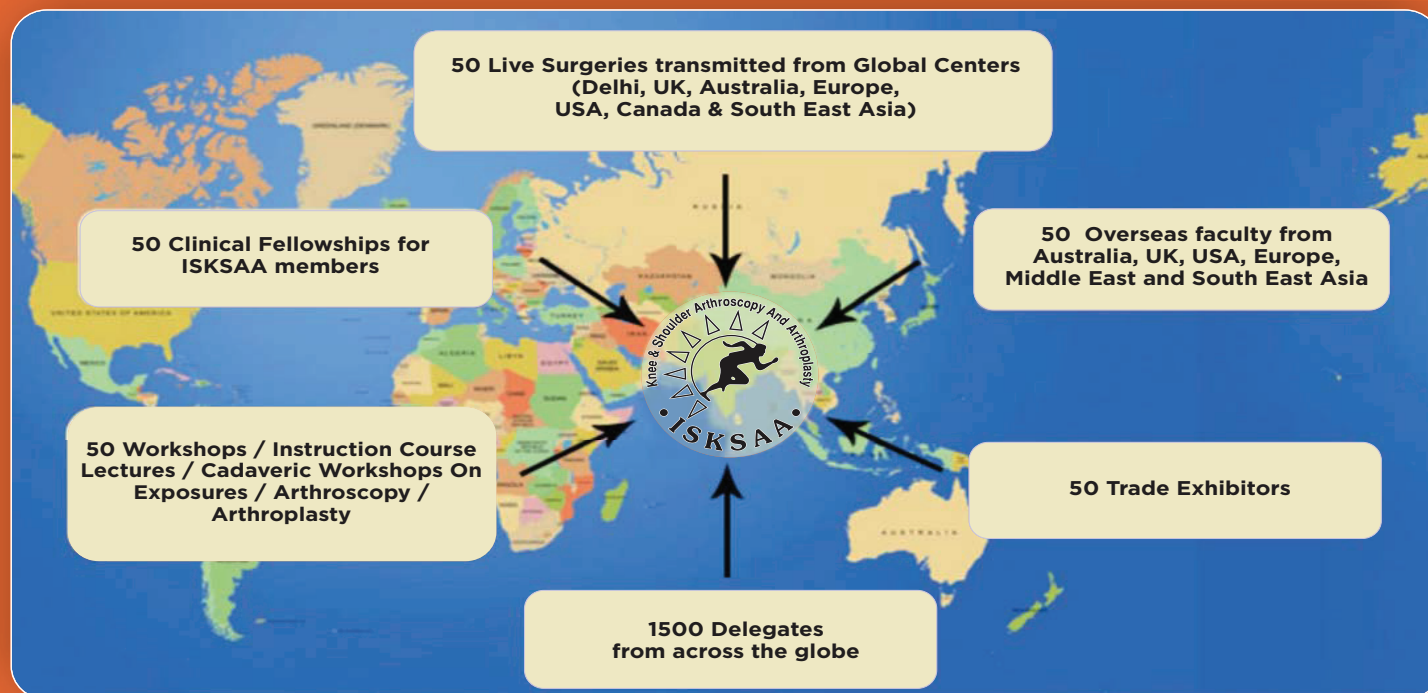
# ISKSAA GLOBAL SUMMIT 2016

10th International Congress of ISKSAA



Preconference Cadaveric Workshops: 20th November 2016, Delhi / NCR

Conference: 21st - 23rd November 2016, The Leela Hotel & Residences, Gurgaon, Delhi/NCR



**ISKSAA SECRETARIAT**  
**Dr Pushpinder Bajaj**  
ISKSAA PRESIDENT

B-7/5, SAFDARJUNG ENCLAVE, NEW DELHI -110029, INDIA  
TEL : +91-11-41057555 / 41057556 / 41057557 MOBILE : +91-9811056525  
EMAIL : isksaapresident@gmail.com  
[www.isksaa.com/isksaa2016](http://www.isksaa.com/isksaa2016)



JOURNAL OF ARTHROSCOPY AND JOINT SURGERY

# JAJJS

Official Journal of the International Society for Knowledge for Surgeons on Arthroscopy and Arthroplasty (ISKSAA)

**Indexed in Scopus**

Volume 3 Number 1 January–April 2016

ISSN: 2214-9635

Available online at [www.sciencedirect.com](http://www.sciencedirect.com)

**ScienceDirect**

JAJJS

VOLUME 3

NUMBER 1

JANUARY–APRIL 2016

PAGES 1–42

ELSEVIER





## ISKSAA International Society for Knowledge for Surgeons on Arthroscopy and Arthroplasty

ISKSAA (International Society for Knowledge for Surgeons on Arthroscopy and Arthroplasty) is a society of orthopaedic surgeons from around the world to share and disseminate knowledge, support research and improve patient care in Arthroscopy and Arthroplasty. We are proud to announce that ISKSAA membership has crossed the **1200** mark (India & Overseas) making it the **fastest growing Orthopaedic Association in the country** in just over 3 years of its inception. With over **190000 hits from over 139 countries** on the website [www.isksaa.com](http://www.isksaa.com) & more and more interested people joining as members of ISKSAA, we do hope that ISKSAA will stand out as a major body to provide opportunities to our younger colleagues in training, education and fellowships.

### Our Goals.....

- To provide health care education opportunities for increasing cognitive and psycho-motor skills in Arthroscopy and Arthroplasty
- To provide CME programs for the ISKSAA members as well as other qualified professionals.
- To provide Clinical Fellowships in Arthroscopy and Arthroplasty
- To provide opportunities to organise and collaborate research projects
- To provide a versatile website for dissemination of knowledge

### ISKSAA Life Membership

The membership is open to Orthopaedic Surgeons, Postgraduate Orthopaedic students and Allied medical personal interested in Arthroscopy & Arthroplasty.

### Benefits of ISKSAA Life membership include....

- Eligibility to apply for **ISKSAA's Prestigious Fellowship Programme**. We are finalising affiliations with ESSKA, ISAKOS, BOA, BASK, Wrightington and FLINDERS MEDICAL CENTRE, IMRI AUSTRALIA to provide more **ISKSAA Fellowships** in India, UK, USA, Australia and Europe. **We awarded 14 ISKSAA Fellowships in Feb 2013, 6 ISKSAA IMRI fellowships in Feb 2014, 54 ISKSAA fellowships in September 2014, 22 ISKSAA Wrightington MCh. fellowships in December 2014 and 40 ISKSAA Fellowships in October 2015 and are awaiting the results of ISKSAA Wrightington MCh. fellowships in December 2015.**
- Free Subscription** of ISKSAA's official, SCOPUS INDEXED, peer reviewed, online scientific journal **Journal of Arthroscopy and Joint Surgery (JAJS)**.
- Only as a life member, you can enjoy the benefit of **reduced Congress charges** in **ISKSAA Global Summit 2016 and participate in the Cadaveric workshops.**
- Member's only section** on the website which has access to the conference proceedings and live surgeries of ISKSAA 2012, 2013 & 2014 along with a host of other educational material.
- Important opportunity for interaction with world leaders in Arthroscopy & Arthroplasty.
- Opportunity to participate in ISKSAA courses and workshops

To enjoy all the benefits & privileges of an ISKSAA member, you are invited to apply for the Life membership of ISKSAA by going to the membership registration section of the website and entering all your details electronically. All details regarding membership application and payment options are available ([www.isksaa.com](http://www.isksaa.com))

### ISKSAA GLOBAL SUMMIT 2016 FELLOWSHIPS

We are happy to announce **over 50 Clinical Fellowships** for ISKSAA 2016 Congress ranging from 2 weeks to 1 month in India and Abroad (UK, USA, Australia & Europe) only for ISKSAA Life members. Applications for Fellowships will open at [www.isksaa.com](http://www.isksaa.com) from **1<sup>st</sup> July 2016** and will close on **31<sup>st</sup> August 2016**. These fellowships will be focussed on Arthroscopy & Arthroplasty and Sports Medicine. Members with Submission or publication of an article in JAJS, completed an ISKSAA Indian Fellowship & earlier membership of ISKSAA will be preferred for the ISKSAA International Fellowships



### LM-VIT GOLD

Co-enzyme10, L-carnitine, L-Arginine  
Lycopene, DHA Combination Tablets

### Calcidura

Calcium Citrate Malate, Cholecalciferol,  
Folic Acid Tablets

### Cyfer tab/syp

Ferrous Ascorbate 100mg EI, Folic Acid 1.5mg  
Syp-Ferrous Ascorbate 30mg EI, Folic Acid .5mg/5ml

### C-Bone Tablet

Cholecalciferol 60000 IU

### Cefulor-500

Cefuroxime 500mg Tablets

### DURACLAV (625/Dry Syrup)

Amoxicillin 500mg, Clavulanate 125mg  
Amoxicillin 200mg, Clavulanate 28.5mg/ 5ml

### Flamazox-MR

Diclofenac 50mg, Paracetamol 325mg  
Chlorzoxazone 250mg Tablets

### Flamazox Gel

Diclofenac Diethylamine 1.16% w/w. +  
Methyl Salicylate 10% w/w. + Menthol 5% w/w.  
+ Oleum Lini 3% w/w.

### Edcort-6

Deflazacort 6mg

### Lorcaine Gel

Oxetacaine, Magnesium, Aluminium Hyd  
Anesthetic Antacid Gel

### Mobilio

Tramadol 37.5 mg + Paracetamol 325mg

### LM-VIT Cap/Syp

Lycopene with Multivitamins  
Multimineral Combination capsules

### Seradura

Nimesulide 100mg, Serratiopeptidase 15mg tablets

### Seradura-AP

Aceclofenac 100mg, Paracetamol 325 mg,  
Serratiopeptidase 15mg Tablets

### Rabidura-DSR

Rabiprazole 20mg, Domperidone 30mg  
(10mgIR + 20mg SR) Capsules

### Skelafit

Collagen Peptide 10g, Glucosamine 1500mg  
Vit C 35mg Sachets

### Mesofose

Co-enzyme10, L-carnitine, L-Arginine  
Lycopene, DHA Combination Tablets

### Magic HP Kit

Amoxicillin 750mg 2 tab + Clarithromycin 500mg 2 tab  
Pantaprazole 40mg 2 cap Combipack

### Edpro Granules

Whey Protein with DHA & GLA Powder

### Ostopure

Diacerin 50mg, Glucosamine 750mg,  
MSM 250 mg Tablets

### Mecosure Cap

Pregabalin 75mg, Methylcobalamin 750mg Cap

### Durazol LS

Pantaprazole 40mg + Levosulpiride 75mg SR Cap

### BMP Forte

Cissus Quadrangularis 750mg, withania somnifera 100mg,  
Embllica Officinalis 50mg, Commiphora wightii 100mg Tablets

### Recent Introduction

## Veziel

(Co Q10 with Amino acids)

## Collagel

(Collagen Peptide 10gm / 25ml)

XYATA LIFESCIENCES LTD.  
HONG KONG  
www.xyata.hk



XYATA LIFESCIENCES PVT. LTD.  
INDIA  
www.xyata.in

*offers the highly specialized range*



## FOR OSTEOARTHRITIS MANAGEMENT

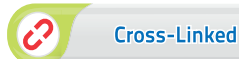Cross Linked

**BIOVISC**  
**ORTHO SINGLE** PFS

Hyaluronic Acid Inj. 3ml (90mg / 3ml)

Optimum Volume, Sustained Effect

90 High Concentration HA



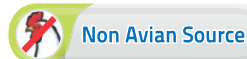Cross-Linked

High Molecular Weight

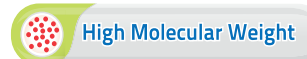**HYNEES**<sup>®</sup>  
PFS

Sodium Hyaluronate Inj. 2ml (10mg / ml)

For effective management of osteoarthritis



Non Avian Source



High Molecular Weight

## FOR OSTEOPOROSIS MANAGEMENT

Recombinant Human Parathyroid Hormone (1-34)

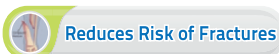**ELEVOSTEO**<sup>®</sup>

Teriparatide Injection (rDNA origin)

**ELEVATING OSTEOGENESIS**



Increases Bone Formation

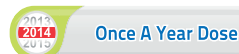

Reduces Risk of Fractures

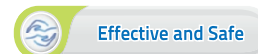**ZOLVOID**<sup>®</sup>

Zoledronic Acid Infusion 5mg/100ml

The **GOLD STANDARD** in Osteoporosis Treatment



Once A Year Dose




Effective and Safe

## For Comprehensive Mobility Solutions

A WHO - GMP Certified Company

NATIONAL TOLL FREE HELPLINE: 1800 1111 55

An ISO : 9001 - 2008 Certified Company



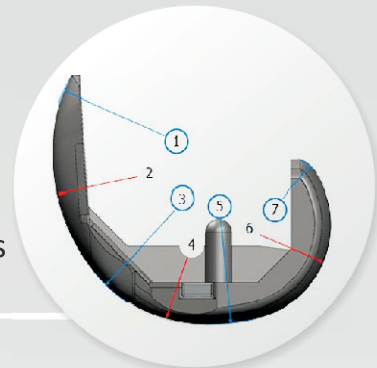
# INTRODUCING PATENTED TECHNOLOGIES FOR INDIANS & ASIANS

Asian & Caucasian Size



High Flexion Implants

The 7-Radius Patented Femoral design reflects natural anatomy and functional principles



## LATITUD™

HIP SYSTEM | Freedom of Choice



Acetabular Cup System & Uncemented Stems



Bi-Polar Cup System & Cemented Stems

A fast growing brand in US and around the globe

Approved by : US FDA | CE European | TGA Australia SFDA  
China and Singapore | DCGI, India

Pursue Life™

### United States

Maxx Orthopedics Inc. 531 Plymouth Road, Suite 526, Plymouth Meeting, PA 19462, USA. W : www.maxxmed.com

### India Sales & Marketing

Meril Life Sciences India Pvt. Ltd. 512, Midas, Sahar Plaza, J.B. Nagar, Andheri East, Mumbai 400 059 Maharashtra. India.  
T : +91 22 4047 9797 W : www.merillife.com



# Journal of Arthroscopy and Joint Surgery

An official publication of International Society for Knowledge for Surgeons on Arthroscopy and Arthroplasty

(ISSN: 2214-9635)

Volume 3, Number 1, January–April 2016

## Aims and Scope

*Journal of Arthroscopy and Joint Surgery* (JAJS) is committed to bring forth scientific manuscripts in the form of original research articles, current concept reviews, meta-analyses, case reports and letters to the editor. The focus of the Journal is to present wide-ranging, multi-disciplinary perspectives on the problems of the joints that are amenable with Arthroscopy and Arthroplasty. Though Arthroscopy and Arthroplasty entail surgical procedures, the Journal shall not restrict itself to these purely surgical procedures and will also encompass pharmacological, rehabilitative and physical measures that can prevent or postpone the execution of a surgical procedure. The Journal will also publish scientific research related to tissues other than joints that would ultimately have an effect on the joint function.

## Author inquiries

You can track your submitted article at <http://www.elsevier.com/track-submission>. You can track your accepted article at <http://www.elsevier.com/trackarticle>. You are also welcome to contact Customer Support via <http://support.elsevier.com>

## Copyright

© 2016, International Society for Knowledge for Surgeons on Arthroscopy and Arthroplasty. Published by Reed Elsevier India Pvt. Ltd. All rights reserved. Papers accepted for publication become the copyright of *International Society for Knowledge for Surgeons on Arthroscopy and Arthroplasty*, and authors will be asked to sign a transfer of copyright form, on receipt of the accepted manuscript by Elsevier. This enables the Publisher to administer copyright on behalf of the Authors, whilst allowing the continued use of the material by the Author for scholarly communication.

**This journal and the individual contributions contained in it are protected under copyright by Elsevier Ltd., and the following terms and conditions apply to their use:**

## Photocopying

Single photocopies of single articles may be made for personal use as allowed by national copyright laws. Permission of the Publisher and payment of a fee is required for all other photocopying, including multiple or systematic copying, copying for advertising or promotional purposes, resale, and all forms of document delivery. Special rates are available for educational institutions that wish to make photocopies for non-profit educational classroom use.

For information on how to seek permission visit <http://www.elsevier.com/permissions> or call: (+44) 1865 843830 (UK) / (+1) 215 239 3804 (USA).

## Derivative Works

Subscribers may reproduce table of contents or prepare lists of articles including abstracts for internal circulation within their institutions. Permission of the Publisher is required for resale or distribution outside the institution. Permission of the Publisher is required for all other derivative works, including compilations and translations (please consult [www.elsevier.com/permissions](http://www.elsevier.com/permissions)).

## Electronic Storage or Usage

Permission of the Publisher is required to store or use electronically any material contained in this journal, including any article or part of an article (please consult [www.elsevier.com/permissions](http://www.elsevier.com/permissions)).

Except as outlined above, no part of this publication may be reproduced, stored in a retrieval system or transmitted in any form or by any means, electronic, mechanical, photocopying, recording or otherwise, without prior written permission of the Publisher.

## Notice

No responsibility is assumed by the Publisher for any injury and/or damage to persons or property as a matter of products liability, negligence or otherwise, or from any use or operation of any methods, products, instructions or ideas contained in the material herein. Because of rapid advances in the medical sciences, in particular, independent verification of diagnoses and drug dosages should be made.

Although all advertising material is expected to conform to ethical (medical) standards, inclusion in this publication does not constitute a guarantee or endorsement of the quality or value of such product or of the claims made of it by its manufacturer.

## Subscription information

The *Journal of Arthroscopy and Joint Surgery* (ISSN: 2214-9635) is published thrice a year. The annual price for **individual subscription** based in India is **INR 3600**; and for international subscribers, the annual price is **USD 60**. For **institutional subscription** within and outside India, please contact the Publishers office at [journals.india@elsevier.com](mailto:journals.india@elsevier.com).

Further information is available on this journal and other Elsevier products through Elsevier's website (<http://www.elsevier.com>). Subscriptions are accepted on a prepaid basis only and are entered on a calendar year basis. Issues are sent by standard mail. Priority rates are available upon request. Claims for missing issues should be made within six months of the date of dispatch.

**Orders, claims, advertisement and journal enquiries:** please contact

**Editorial Office:** Dr Pushpinder Singh Bajaj, Bajaj Specialist Clinics, B-7/5 Safdarjung Enclave, New Delhi – 110029. Tel: 41057555 / 41057556 / 41057557. Email: [psbajaj@hotmail.com](mailto:psbajaj@hotmail.com).

**Publishing Office:** Elsevier, A division of Reed Elsevier India Pvt. Ltd., 14th Floor, Building No.10B, DLF Cyber City, Phase-II, Gurgaon-122002, Haryana, India. Email: [journals.india@elsevier.com](mailto:journals.india@elsevier.com)





# Journal of Arthroscopy and Joint Surgery

An official publication of International Society for Knowledge for Surgeons on Arthroscopy and Arthroplasty

(ISSN: 2214-9635)

Volume 3, Number 1, January–April 2016

## Editor-in-Chief

PROF RAVI GUPTA Chandigarh

MR SANJEEV ANAND UK

## Executive Editor

PROF LALIT MAINI Delhi

## Managing Editor

DR PUSHPINDER BAJAJ Delhi

## Deputy Editor

DR AMITE PANKAJ Delhi

## Section Editors

### Trauma & Rehabilitation

DR ALEXANDER WOOD UK

### Hip

DR AJAY AGGARWAL USA

### Foot & Ankle

DR MUNEEESH BHATIA UK

### Training & Education

DR JANAK MEHTA Australia

### Arthroplasty

DR MANOJ SOOD UK

### Pediatric Orthopaedics

DR PARMANAND GUPTA Chandigarh

### Orthopaedic Oncology

DR MANISH PARUTHI Mumbai

### Elbow, Wrist & Hand

DR RAJ MURALI UK

### Shoulder

DR AMOL TAMBE UK

## Associate Editors

DR DINESH PATEL USA  
DR PONKY FIRER South Africa

PROF JEGAN KRISHNAN Australia  
DR GURINDER BEDI Delhi

DR RAJESH SETHI UK  
DR DINSHAW PARDIWALA Mumbai

## Editorial Board

PROF GIANNOUDIS UK  
PROF AMAR RANGAN UK  
DR KHALID MOHAMMAD New Zealand  
MR KAPIL KUMAR UK  
DR MAKARAM SRINIVASAN UK

DR V BHALAIK UK  
DR PUNEET MONGA UK  
DR TAOFEK ADEYEMI Nigeria  
DR MS DHILLON Chandigarh  
DR VIVEK PANDEY Karnataka

DR SUNDARARAJAN Coimbatore  
DR ASHISH DEVGAN Rohtak  
DR RAJU EASWARAN Delhi  
DR RAHUL KHARE Delhi

## Advisory Board

DR ANDREAS SETTJE Germany  
DR ANANT JOSHI Mumbai  
DR ASHOK RAJGOPAL Gurgaon  
DR ASHISH BABULKAR Pune  
DR ASIT SHAH USA  
DR ANIL BHAT Karnataka  
MR BINOD SINGH UK  
DR BINU THOMAS Tamil Nadu  
DR DAVID MARTIN Australia  
DR DAVID RAJAN Coimbatore  
DR DENNY LIE Singapore  
DR EDWARD T MAH Australia  
DR GRAHAM MERCER South Australia  
DR H K WONG Hong Kong

DR HIROYUKI SUGAYA Japan  
DR HITESH GOPALAN Cochin  
PROF J E MENDES Portugal  
DR JAAP WILLEMS Holland  
DR JOHN EBNEZAR Bangalore  
DR JVS VIDYASAGAR Hyderabad  
PROF LENNARD FUNK UK  
DR MARIO PENTA South Australia  
DR NICK WALLWORK South Australia  
DR NIRBHAY SHAH Rajkot  
DR PAOLO PALADINI Italy  
DR PARAG SANCHETI Pune  
DR PETER CAMPBELL Australia  
PROF PP KOTWAL Delhi

PROF RAJASEKARAN Coimbatore  
MR RAM VENKATESH UK  
MR R PANDEY UK  
PROF RAJ BAHADUR Chandigarh  
MR ROBERT J GREGORY UK  
DR ROHIT ARORA Austria  
DR SACHIN TAPASVI Pune  
DR SANJAY DESAI Mumbai  
DR SANJAY GARUDE Mumbai  
DR SANJAY TRIVEDI Ahmedabad  
DR SRIPATHI RAO Karnataka  
PROF SUDHIR KAPOOR Delhi  
MR VED GOSWAMI UK  
DR YOUNG LAE MOON Korea

Copyright (C) 2016, International Society for Knowledge for Surgeons on Arthroscopy and Arthroplasty. All rights reserved.

Published by Reed Elsevier India Pvt. Ltd.

No part of the publication may be transmitted in any form or by any means, electronic or mechanical, without written permission from the Editor-in-Chief.

*Disclaimer: Although all advertising material is expected to conform to ethical (medical) standards, inclusion in the publication does not constitute a guarantee or endorsement of the quality or value of such product or of the claims made of it by its manufacturer. Please consult full prescribing information before issuing prescriptions for any products mentioned in this publication.*

Printed at EIH Limited-Unit Printing Press, IMT Manesar, Gurgaon





# Journal of Arthroscopy and Joint Surgery

An official publication of International Society for Knowledge for Surgeons on Arthroscopy and Arthroplasty

(ISSN: 2214-9635)

Volume 3, Number 1, January–April 2016

## Table of Contents

### Editorial

Editorial <i>Ravi Gupta</i>	1
--------------------------------	---

### Original Articles

Humeral avulsion of glenohumeral ligaments – Detection on magnetic resonance arthrography <i>Rukhtam Saqib, Lennard Funk, Jonathan Harris</i>	3
Arthroscopic fixation using TightRope device for acute acromioclavicular joint disruptions <i>Paras Gupta, Gagan Kansal, Shekhar Srivastav, Shekhar Agarwal</i>	7
Arthroscopic stabilization of acute acromioclavicular joint dislocation with tightrope AC system: A tale of failures <i>Shreesh Kumar Gangary, Sanjay Meena</i>	13
Comparison of CT-based patient-specific templating and digital radiography templating in total knee arthroplasty <i>Rutul R. Gandhi, Alfonso Manzotti, Norberto Confalonieri, Peitro Cerveri</i>	17
A radiological comparative study between transtibial & anteromedial portal drilling of femoral tunnel in single bundle anterior cruciate ligament reconstruction: A comparison of four angles <i>Siddharth M. Shetty, Vikram Shetty, Arjun Ballal, Jeetu Mohanchandran, Anoop Hegde</i>	22
Mucoid degeneration of the anterior cruciate ligament: Partial arthroscopic debridement and outcomes <i>Gagan Khanna, Rajan Sharma, Aditya Bhardwaj, Harjot S. Gurdutta, Deepak K. Agrawal, Abhishek S. Rathore</i>	28

### Case Reports

Intra-articular lipoma arborescence of the knee – A rare clinical entity <i>Vivek Pandey, Arun Gupta, Smita Kulshrestha, Lipisha Agarwal</i>	34
Vertical intraarticular dislocation of patella <i>Amit Chauhan, Shanmuga Maheswaran, Sanjeev Anand</i>	39





Available online at [www.sciencedirect.com](http://www.sciencedirect.com)

ScienceDirect

journal homepage: [www.elsevier.com/locate/jajs](http://www.elsevier.com/locate/jajs)

## Editorial



The current issue of JAJ S contains two original papers reporting the outcome of surgical management of acromioclavicular (A.C) joint injuries by arthroscopic tight rope stabilization. Both the studies are prospective studies and have 10 and 11 patients, respectively. Both the papers have included Rockwood grade III to grade V A.C joint injuries. The similar surgical technique used by both the authors, however, has not produced similar outcomes. The first series of Gupta et al. has reported seven excellent, two good and one fair result. While Gangary et al. in their series have reported one good, seven satisfactory and two poor outcomes. The second study has reported six failures of a total number of 11 shoulders. Two shoulders required revision surgery. Of the six failed cases, four belonged to grade III injury.

Arthroscopic assisted reconstruction with non-rigid coraco-clavicular (CC) lacing is a relatively new method of surgical stabilization of the A.C joint. The main advantages of this method include better cosmetic result, shorter time of surgery, no intra-operative fluoroscopy and reduced post-surgical morbidity due to minimal invasive nature of the surgery.<sup>1,2</sup> However, the method involves a higher cost of the implant and requires a surgeon well versed with the procedure of arthroscopy.<sup>3</sup>

Some of the recent studies have shown successful outcome with coraco-clavicular lacing procedures including tight rope.<sup>1,2,4–6</sup> On the contrary, there are studies which have reported unfavorable results with these surgical procedures. Clavert et al. in a prospective multi-centric study of 116 patients have reported 50% significant persistent dislocations after arthroscopic endobutton coraco-clavicular procedures with a complication rate of 22.4%.<sup>7</sup> Similarly, Barth et al. in a multicentric study have concluded that coracoclavicular stabilization alone is not sufficient irrespective of the implant used.<sup>8</sup>

Loriaut et al. have also reported 7% patients requiring revision surgery because of persistence of dislocation after arthroscopic assisted reconstruction of A.C. joint.<sup>9</sup>

Thus the results of arthroscopic non-rigid CC fixation, in the current literature are mixed. Whether the diagonally opposite outcomes are related to variations in patient selection or execution of the surgical technique is still unknown.

But a universal similarity in all the studies emanating from single centers is that the series are small with less number of patients thus reducing the power of study. Reporting of larger case series from individual centers will certainly take out the factor of the learning curve of the surgeon, in addition to enhancing the power of the study thus eliminating the chance factor.

## REFERENCES

1. Darabos N, Vlahovic I, Gusic N, Darabos A, Bakota B, Miklic D. Is AC TightRope fixation better than Bosworth screw fixation for minimally invasive operative treatment of Rockwood III AC joint injury? *Injury*. 2015;46(suppl 6):S113–S118.
2. Vrgoč G, Japjec M, Jurina P, et al. Operative treatment of acute acromioclavicular dislocations Rockwood III and V-Comparative study between K-wires combined with FiberTape(®) vs. TightRope System(®). *Injury*. 2015;46(suppl. 6):S107–S112.
3. Horst K, Dienstknecht T, Pishnamaz M, Sellei RM, Kobbe P, Pape HC. Operative treatment of acute acromioclavicular joint injuries graded Rockwood III and IV: risks and benefits in tight rope technique vs. k-wire fixation. *Patient Saf Surg*. 2013;7:18.
4. Andreani L, Bonicoli E, Parchi P, Piolanti N, Michele L. Acromio-clavicular repair using two different techniques. *Eur J Orthop Surg Traumatol*. 2014;24(2):237–242.
5. Jensen G, Ellwein A, Voigt C, Katthagen JC, Lill H. Injuries of the acromioclavicular joint: hook plate versus arthroscopy. *Unfallchirurg*. 2015;118(12):1041–1055.
6. Natera-Cisneros L, Sarasquete-Reiriz J, Escolà-Benet A, Rodríguez-Mirallés J. Acute high-grade acromioclavicular joint injuries treatment: arthroscopic non-rigid coracoclavicular fixation provides better quality of life outcomes than hook plate ORIF. *Orthop Traumatol Surg Res*. 2016;102(1):31–39.
7. Clavert P, Meyer A, Boyer P, Gastaud O, Barth J, Duparc F. Complication rates and types of failure after arthroscopic acute acromioclavicular dislocation fixation. Prospective multicenter study of 116 cases. *Orthop Traumatol Surg Res*. 2015;101(8 suppl.):S313–S316.
8. Barth J, Duparc F, Andrieu K, et al. Is coracoclavicular stabilisation alone sufficient for the endoscopic treatment of severe acromioclavicular joint dislocation (Rockwood types III, IV, and V)? *Orthop Traumatol Surg Res*. 2015;101(8 suppl.):S297–S303.
9. Loriaut P, Casabianca L, Alkhaili J, et al. Arthroscopic treatment of acute acromioclavicular dislocations using a

double button device: clinical and mri results. *Orthop  
Traumatol Surg Res.* 2015;101(8):895–901.

Received 7 March 2016

Received in revised form 9 March 2016

Accepted 15 March 2016


Ravi Gupta, MS, DNB, FAMS, FIMSA  
Professor, Department of Orthopaedics,  
Government Medical College Hospital,  
Chandigarh 160031, India

E-mail address: ravikgupta2000@yahoo.com

[http://dx.doi.org/10.1016/S2214-9635\(16\)30003-7](http://dx.doi.org/10.1016/S2214-9635(16)30003-7)  
2214-9635/

Available online at [www.sciencedirect.com](http://www.sciencedirect.com)

ScienceDirect

journal homepage: [www.elsevier.com/locate/jajs](http://www.elsevier.com/locate/jajs)

## Original Article

# Humeral avulsion of glenohumeral ligaments – Detection on magnetic resonance arthrography

Rukhtam Saqib<sup>a,\*</sup>, Lennard Funk<sup>b</sup>, Jonathan Harris<sup>c</sup><sup>a</sup> Foundation Year 2, Stepping Hill Hospital, Stockport, UK<sup>b</sup> Consultant Orthopaedic Surgeon, Wrightington Hospital, UK<sup>c</sup> Consultant Musculoskeletal Radiologist, Salford Royal Hospital, Manchester, UK

## ARTICLE INFO

## Article history:

Received 6 December 2015

Accepted 22 February 2016

Available online 22 March 2016

## Keywords:

Arthroscopy

Magnetic resonance arthrography

HAGL

Sensitivity

Prevalence

## ABSTRACT

**Background:** Humeral avulsion of the glenohumeral ligaments (HAGL) is an important cause of shoulder instability, with magnetic resonance arthrography (MRA) routinely being used for diagnosis. Our aim was to compare the diagnostic value of MRA to shoulder arthroscopy for the detection of HAGL lesions and to calculate its prevalence.

**Methods:** Patients who underwent a shoulder arthroscopy with a single surgeon and pre-operative MRA between February 2011 and March 2012 for instability were identified. MRAs were reported by experienced musculoskeletal radiologists and compared to arthroscopy findings for the presence of HAGL lesions. Sensitivity, specificity, positive and negative predictive values, prevalence and positive and negative likelihood ratios were calculated. **Results:** A total of 194 patients were identified with a HAGL lesion prevalence of 4.64% on arthroscopy. The sensitivity of MRA in detecting HAGL was 0.44 (CI: 0.14–0.79) and the specificity was 0.97 (CI: 0.94–0.99). The positive predictive value was 0.44 (CI: 0.14–0.79) and negative predictive value was 0.97 (CI: 0.94–0.99). The positive likelihood ratio was 16.44 (CI: 5.30–51.00) and negative likelihood ratio was 0.57 (CI: 0.32–1.02).

**Conclusions:** MRA appears to be specific and accurate in excluding HAGL lesions, but not sensitive. HAGLs were associated with numerous other injuries such as bankart, SLAP and Hill–Sach lesions. The prevalence of 4.64% is comparable to previous studies.

© 2016 International Society for Knowledge for Surgeons on Arthroscopy and Arthroplasty. Published by Elsevier, a division of Reed Elsevier India, Pvt. Ltd. All rights reserved.

## 1. Introduction

Humeral avulsion of glenohumeral ligaments (HAGL) is an important cause of shoulder instability.<sup>1</sup> Instability usually arises as a result of acute trauma from glenohumeral subluxation or dislocation, with a combination of hyperabduction

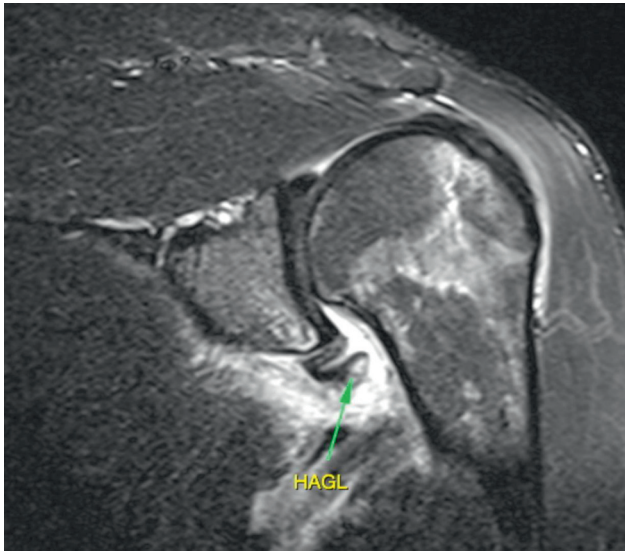
and external rotation.<sup>2</sup> MRA is well established in assessing glenohumeral pathology but its role in identifying HAGL lesions is under-reported in literature.<sup>3</sup> Jana et al. and Carlson described the J-sign referring to the conversion of the U-shaped axillary pouch to a J-shape as the inferior glenohumeral ligament (IGHL) complex drops inferiorly.<sup>3,4</sup> Other characteristics include increased intensity, thickening of the inferior capsule, a

\* Corresponding author. Tel.: +44 7719491775; fax: +44 7719491775.

E-mail address: [rukhtamsaqib@doctors.org.uk](mailto:rukhtamsaqib@doctors.org.uk) (R. Saqib).

<http://dx.doi.org/10.1016/j.jajs.2016.02.001>

2214-9635/© 2016 International Society for Knowledge for Surgeons on Arthroscopy and Arthroplasty. Published by Elsevier, a division of Reed Elsevier India, Pvt. Ltd. All rights reserved.



**Fig. 1 – A MRA demonstrating a HAGL lesion.**

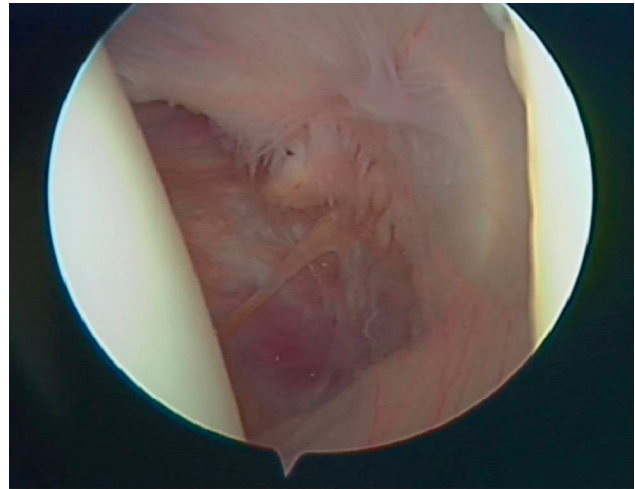
thickened wavy contour and higher intensity within the ligament itself, and extravasation of contrast material along the humeral neck (Fig. 1).<sup>3,4</sup>

Shoulder arthroscopy is the gold standard in detecting HAGL lesions through direct visualisation.<sup>5</sup> The distinguishing sign is visualisation of fibres of the subscapularis through the avulsed inferior joint capsule.<sup>6</sup> Bokor et al. described a disruption of the 'wave' between the reflection of the inferior capsule onto the humeral neck to be a reliable sign of HAGL lesions.<sup>7</sup>

The aim of our study is to assess the diagnostic value of MRA in detecting HAGL lesions compared with arthroscopy and to calculate the prevalence within our study group (Fig. 2).

## 2. Materials and methods

Shoulder arthroscopies performed by a single Consultant Orthopaedic Surgeon between February 2011 and March 2012 for instability were identified using the surgeon's operative records. All patients attended an initial outpatient clinic and were found to have clinical instability on examination, with suspicion of glenohumeral pathology including the possibility of a HAGL lesion. Of these patients, only those who had a pre-operative MRA were included and identified through PACS (Centricity PACS, GE Healthcare), Bluespир (Bluespир International, Droitwich, UK) and clinic letters. Patients were included regardless of demographics, background, side of operation or indication. The MRAs were requested by the Orthopaedic Surgeon to ensure that radiologists were made aware of the positive clinical findings on the request forms. The investigations and procedures were conducted over three hospital sites. 1.5T MRI scanners with gadolinium as contrast were used throughout with a routine standard protocol of T1 and T1 fat-sat axial, T1 fat-sat coronal and sagittal obliques, T2 fat-sat coronal oblique. All MRAs were reported by experienced specialist musculoskeletal radiologists. Findings were only included as positive when the radiologists or arthroscopist were definitive in their diagnosis.



**Fig. 2 – A HAGL lesion on shoulder arthroscopy.**

### 2.1. Statistics

Sensitivities, specificities, positive and negative predictive values (PPV/NPV), positive and negative likelihood ratios (PLR/NLR) were calculated using Statistical Package for Social Sciences (SPSS) version 22.0 (SPSS Inc. Chicago, IL, USA, 2014).

## 3. Results

A total of 744 patients underwent shoulder arthroscopic procedures for instability, of which 194 patients had a pre-operative MRA. Patients whose pathology was easily identifiable, or not related to a HAGL, on clinical examination or simpler radiological investigations such as ultrasound and X-rays did not have an MRA. The mean age was 29.9 years with a range between 13 and 69 years. 73%/27% of patients were males/females. Right to left ratio was nearly equal (52%:48%).

The prevalence of HAGL lesions on arthroscopy was 4.64% (9/194 cases). There were 4 true positives, 180 true negatives, 5 false positives and 5 false negatives. The sensitivity and specificity was 0.44 (CI: 0.14–0.79) and 0.97 (CI: 0.94–0.99) respectively. The PPV was 0.44 (CI: 0.14–0.79) and NPV was 0.97 (CI: 0.94–0.99). The PLR was 16.44 (CI: 5.30–51.00) and NLR was 0.57 (CI: 0.32–1.02). Table 1 summarises the statistical analysis.

**Table 1 – A table to show the sensitivity, specificity, positive likelihood ratios (PLR), negative likelihood ratios (NLR), positive predictive value (PPV) and negative predictive value (NPV) with 95% confidence intervals.**

Statistical test	Value	95% confidence intervals
Sensitivity	0.44	0.14–0.79
Specificity	0.97	0.94–0.99
Positive likelihood ratio	16.44	5.30–51.00
Negative likelihood ratio	0.57	0.32–1.02
Positive predictive value	0.44	0.14–0.79
Negative predictive value	0.97	0.94–0.99



Of the 9 confirmed cases of HAGLs on arthroscopy, 8/9 had an associated bankart lesion, 1/9 had an anterior labral periosteal sleeve avulsion (ALPSA), 3/9 had a superior labral tear from anterior to posterior (SLAP), 4/9 had a Hill–Sachs lesion and 2/9 had a rotator cuff tear.

#### 4. Discussion

The diagnostic value of MRA in identifying HAGL lesions has been largely under-reported.<sup>5</sup> Acid et al. compared MRA and multidetector computed tomography (MDCT) to arthroscopy and found that MRA had a sensitivity/specificity of 1.00/0.97 for humeral avulsion of IGHL lesion and 0.58/0.95 for middle glenohumeral ligament tear.<sup>5</sup> Our study showed a lower sensitivity and specificity of 0.44 (CI: 0.14–0.79) and 0.97 (CI: 0.94–0.99) for HAGL lesions. In our study, the presence of any glenohumeral ligament avulsion was considered as a HAGL lesion regardless of position which may account for the differences in statistics. Furthermore, our series was much larger with 194 patients in comparison to 40 patients, which may account for further differences.

Bigliani et al. suggested that avulsion of the IGHL would occur in up to 25% of cases with anterior dislocation in biomechanical cadaveric studies.<sup>8</sup> However, the actual prevalence has been reported to be much less in patients among literature. Wolf et al. were first to demonstrate a prevalence of 9.3% in 64 patients with shoulder instability, of which 73.5% also had a bankart lesion.<sup>6</sup> Yiannakopoulos et al. found that HAGL lesions had a prevalence of 1.57% in 127 patients with anterior shoulder instability.<sup>9</sup> Magee analysed 1000 magnetic resonance imaging (MRI) reports and found a prevalence of 1.6% on MRI and 2.1% in those who proceeded to surgery.<sup>10</sup> Liavaag et al. showed a prevalence of 21.4% of HAGL lesions on MRI in patients with traumatic shoulder dislocation and 7.1% on MRA at follow-up.<sup>11</sup> Bokor et al. found an incidence of 7.5% of HAGL lesions in 514 patients with primary instability on arthroscopy.<sup>7</sup> The incidence of HAGLs rose to 39% in patients who did not have a bankart lesion and violent injury was the cause of the initial dislocation.<sup>7</sup> Bhatia et al. found 11% of patients with bony instability had a HAGL lesion in a 64 patient series.<sup>12</sup> Bui-Mansfield et al. found an incidence of 2% for HAGL lesions in 307 patients who had a diagnostic arthroscopy for glenohumeral instability.<sup>13</sup> Mizuno et al. found a total incidence of 4.6% (14 patients) for HAGLs in 303 shoulders with recurrent dislocations and 4% (12 patients) had an isolated HAGL.<sup>14</sup> The prevalence and population age in our study of 4.64% and mean age 29.9 years is comparable to these studies.

There are several limitations of our study: firstly, a 100% commitment to the diagnosis with terms such as 'possible' and 'cannot exclude' being identified as a negative finding. Time elapsed between the MRA and shoulder arthroscopy could account for worsening or improving pathology and possibly subsequent additional injury leading to the development of a HAGL lesion. MRA reports were available to the arthroscopist prior to the procedure, which may have added an element of bias. However, we tried to minimise this by standardising the method of the procedure to assess the presence of specific glenohumeral pathology regardless of the

MRA. Nevertheless, clinical findings were available to both the radiologist and arthroscopist prior to their assessments. Furthermore, arthroscopy, although gold standard, is imperfect due to its operator-dependant nature and may result in overlooked pathology as well.

#### 5. Conclusion

In our study, we found large 95% confidence interval for PPV, PLR/NLR and sensitivity. It is therefore difficult to ascertain definitive conclusions upon diagnostic value with these statistics. Nevertheless, we are able to conclude that MRA is specific and able to predict a negative result with smaller 95% confidence intervals, but it is limited as a diagnostic tool for HAGLs due to its poor ability to produce a definitive positive result. However, by performing a MRA, the shoulder can be examined for concurring pathologies, which may provide an alternative or concurrent diagnosis. A much larger scale study with greater number of cases assessing the diagnostic value of MRA for HAGL lesions is necessary to explore the true potential of MRA. An additional study comparing MRA and MRI would help establish any further benefit, if any, for the more invasive MRA.

#### Conflicts of interest

All authors have none to declare.

#### REFERENCES

- George MS, Khazzam M, Kuhn JE. Humeral avulsion of glenohumeral ligaments. *J Am Acad Orthop Surg.* 2011;19(March (3)):127–133.
- Martetschläger F, Ames JB, Millett PJ. HAGL and reverse HAGL lesions. *Shoulder Arthrosc.* 2014;411–418.
- Jana M, Srivastava DN, Sharma R, et al. Spectrum of magnetic resonance imaging findings in clinical glenohumeral instability. *Indian J Radiol Imaging.* 2011;21(April–June (2)):98–106.
- Carlson CL. The J sign. *Radiology.* 2004;232(September (3)):725–726.
- Acid S, Le Corroller T, Aswad R, Pauly V, Champsaur P. Preoperative imaging of anterior shoulder instability: diagnostic effectiveness of MDCT arthrography and comparison with MR arthrography and arthroscopy. *Am J Roentgenol.* 2012;198:661–667.
- Wolf EM, Cheng JC, Dickson K. Humeral avulsion of glenohumeral ligaments as a cause of anterior shoulder instability. *Arthroscopy.* 1995;11(October (5)):600–607.
- Bokor DJ, Conboy VB, Olson C. Anterior instability of the glenohumeral joint with humeral avulsion of the glenohumeral ligament. A review of 41 cases. *J Bone Jt Surg Br.* 1999;81(January (1)):93–96.
- Bigliani LU, Pollock RG, Soslowky LJ, Flatow EL, Pawluk RJ, Mow VC. Tensile properties of the inferior glenohumeral ligament. *J Orthop Res.* 1992;10:187–197.
- Yiannakopoulos CK, Mataragas E, Antonogiannakis E. A comparison of the spectrum of intra-articular lesions in acute and chronic anterior shoulder instability. *Arthroscopy.* 2007;23(September (9)):985–990.

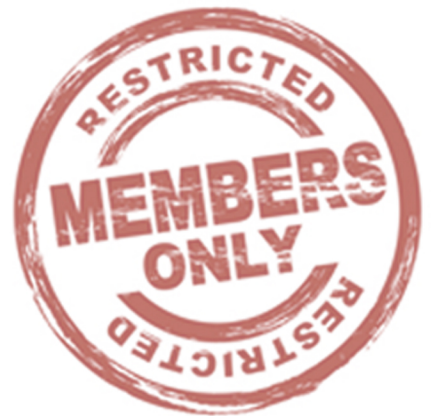

10. Magee T. Prevalence of HAGL lesions and associated abnormalities on shoulder MR examination. *Skelet Radiol.* 2014;43(March (3)):307-313.
11. Liavaag S, Stiris MG, Svenningsen S, Enger M, Pripp AH, Brox JI. Capsular lesions with glenohumeral ligament injuries in patients with primary shoulder dislocation: magnetic resonance imaging and magnetic resonance arthrography evaluation. *Scand J Med Sci Sports.* 2011;21(December (6)):e291-e297.
12. Bhatia DN, DasGupta B. Surgical treatment of significant glenoid bone defects and associated humeral avulsions of glenohumeral ligament (HAGL) lesions in anterior shoulder instability. *Knee Surg Sports Traumatol Arthrosc.* 2013;21(July (7)):1603-1609.
13. Bui-Mansfield LT, Taylor DC, Uhorchak JM, Tenuta JJ. Humeral avulsions of the glenohumeral ligament: imaging features and a review of the literature. *Am J Roentgenol.* 2002;179:649-655.
14. Mizuno N, Yoneda M, Hayashida K, Nakagawa S, Mae T, Izawa K. Recurrent anterior shoulder dislocation caused by a midsubstance complete capsular tear. *J Bone Jt Surg Am.* 2005;87(December (12)):2717-2723.



**To read all articles of this issue, you must be a member of ISKSAA.**

**If you are already a member of  
ISKSAA then please login to access the full issue.**





**To read all articles of this issue, you must be a member of ISKSAA.**

**If you are already a member of  
ISKSAA then please login to access the full issue.**





# Over Four Centuries of Publishing Experience!






With deep roots in health sciences publishing, Elsevier helps doctors advance practice of medicine by providing world-class information which helps them make critical decisions and improve patient outcomes.

Elsevier brings to you over 2,000 health sciences journals, and works with over 7,000 journal editors, 70,000 editorial board members, 300,000 reviewers and 600,000 authors. As the world's leading publisher of science and health information, Elsevier brings to you knowledge products including:

- *The Lancet*
- *The Clinics of North America*
- *Gray's Anatomy*
- *Nelson's Pediatrics*
- *Dorland's Illustrated Medical Dictionary*
- *Netter's Atlas of Human Anatomy*



## Leading Indian Journals from the House of Elsevier



For advertisement and subscription enquiries in Elsevier journals,  
please write to [journals.india@elsevier.com](mailto:journals.india@elsevier.com)





# Over Four Centuries of Publishing Experience!





With deep roots in health sciences publishing, Elsevier helps doctors advance practice of medicine by providing world-class information which helps them make critical decisions and improve patient outcomes.

Elsevier brings to you over 2,000 health sciences journals, and works with over 7,000 journal editors, 70,000 editorial board members, 300,000 reviewers and 600,000 authors. As the world's leading publisher of science and health information, Elsevier brings to you knowledge products including:

- *The Lancet*
- *The Clinics of North America*
- *Gray's Anatomy*
- *Nelson's Pediatrics*
- *Dorland's Illustrated Medical Dictionary*
- *Netter's Atlas of Human Anatomy*



## Leading Indian Journals from the House of Elsevier



For advertisement and subscription enquiries in Elsevier journals,  
please write to [journals.india@elsevier.com](mailto:journals.india@elsevier.com)





## Our Products

IN OSTEOPOROSIS

R<sub>x</sub>

Cap.



**SARVACAL**<sup>TM</sup>  
Calcium Carbonate with Calcitriol  
& Zinc Softgel Capsules

*The Essential Calcium*

*In Low Back Pain & Arthritis*

R<sub>x</sub>

Tab.



**ANKON**<sup>TM</sup> **90 / 120**  
Etoricoxib 90/120 mg

*Lets Your Patient Move ON...*

IN VITAMIN D DEFICIENCY

R<sub>x</sub>

Cap.



**D-3 ONCE**<sup>TM</sup>  
(Cholecalciferol 60,000 IU)

*The Vitamin That Matter*

In Co - R<sub>x</sub> With NSAID

R<sub>x</sub>

Cap.



**Rabbitrol D**<sup>TM</sup>

(Rabeparazole 20 mg + Domperidome 30mg SR)

Helpline : 9582874697

All products are available at 98.4 Chemist Retail Chain